



Progressive cerebellar ataxia and new-onset diabetes

Marie-France Kong, Gérald Glibert, Felicia Baleanu, Rafik Karmali

Lancet 2014; 383: 186

Centre Hospitalier Universitaire Brugmann, Bruxelles, Belgium (M-F Kong FRCP, G Glibert MD, F Baleanu MD, R Karmali PhD); and University Hospitals of Leicester NHS Trust, Leicester, UK (M-F Kong MD)

Correspondence to: Dr Marie-France Kong, Department of Diabetes & Endocrinology, University Hospitals of Leicester NHS Trust, Leicester General Hospital, Gwendolen Road, Leicester LE5 4PW, UK
marie-france.kong@uhl-tr.nhs.uk

In October, 2012, a 37-year-old Rwandan businessman was transferred to our hospital from Nairobi, Kenya, where he had been investigated for subacute onset of progressive cerebellar ataxia and quadriplegia of unclear cause. He presented initially to a hospital in Nairobi in August, 2012, with a 2–3 week history of imbalance and weakness, as well as back pain and stiffness, without cognitive or systemic symptoms. He had no history of preceding infection or vaccination and the only recent travel had been to Dubai and Europe. Over the following 6 weeks his symptoms progressed and he became more unsteady on his feet, and unable to stand without support. He developed speech difficulty with mild dysphagia, and reported blurred vision. On examination at our hospital, he had noticeable cerebellar dysarthria, appendicular cerebellar signs, and pronounced truncal ataxia. Limb motor strength and sensation were normal. He had no diplopia and no nystagmus. Hypertropia, convergence insufficiency, and hypometric and slow saccades, especially in the upward gaze, were present, suggesting brainstem involvement. Cognition was normal. MRI of brain and spine was normal apart from a few non-specific small white matter hyperintensities. Nerve conduction studies and electromyography were normal. Detailed laboratory profile was normal apart from fasting blood glucose of 8.6 mmol/L. Lumbar puncture revealed a raised IgG index and the presence of oligoclonal IgG bands. CSF protein and cytology were normal. A paraneoplastic syndrome was considered but investigations were negative. FDG-PET revealed a depressed glucose metabolism in the cerebellum and in the right thalamus (figure). Immunoblotting for diagnosis of antineuronal antibodies was negative. A repeat fasting glucose of 9.0 mmol/L confirmed diabetes and the patient was started on metformin. He had no family history of diabetes or of autoimmune diseases. Autoantibodies to glutamic acid decarboxylase (GAD-ab) were checked: the concentration was very high (> 250 IU/mL). Islet cell antibodies (ICA) were positive at a titre of 25600. Other autoantibodies were negative.

A diagnosis of autoimmune cerebellar ataxia was suspected and confirmed by the presence of high titres

of GAD-ab in the CSF. The patient was treated with high doses of steroids and pulses of intravenous cyclophosphamide. Although there was a diminution in the serum GAD-ab titres, improvement in symptoms after 9 months was minimal (the patient was last seen in July, 2013, when he returned to Nairobi). Follow-up MRI brain scan did not show any changes, in particular no cerebellar atrophy. 9 months after diagnosis of his diabetes his blood sugars remain well controlled on metformin only.

Autoimmune cerebellar ataxia related to GAD-ab is a rare condition that typically affects women with late-onset type 1 diabetes or other autoimmune disorders.^{1,2} Cerebellar ataxia, the second most common syndrome associated with high GAD-ab values, shares the same demographic, clinical, and immunological features with stiff person syndrome.³ The demonstration of an increased intrathecal synthesis of GAD-ab is important to confirm that the GAD autoimmunity is related to the neurological syndrome, especially when there is concomitant type 1 diabetes that could explain the presence of high GAD-ab.³ GAD-ab concentrations in patients with cerebellar ataxia and in patients with stiff person syndrome are substantially higher than values in those with a recent diagnosis of type 1 diabetes. Not all patients with cerebellar ataxia and GAD-ab have diabetes. The pathogenic role of autoimmunity and GAD-ab in cerebellar ataxia remains unclear but it seems that GAD-abs are directly responsible for the pathogenesis of the cerebellar ataxia.⁴ Our patient most likely has latent autoimmune diabetes of the adult. Prospective studies of β -cell function show that such patients with multiple islet antibodies develop β -cell failure within 5 years, whereas those with only GAD-ab or only ICAs mostly develop β -cell failure after 5 years.⁵

Acknowledgments

We thank Professor Anne Sophie Hambye for providing the FDG-PET image.

Contributors

M-FK and GG looked after the patient, did the literature search and wrote the Case Report. FB and RK were involved in the care of the patient. Written consent to publish was obtained.

References

- Honnorat J, Saiz A, Giometto, et al. Cerebellar ataxia with anti-glutamic acid decarboxylase antibodies. Study of 14 patients. *Arch Neurol* 2001; **58**: 225–30.
- Pittock SJ, Yoshikawa H, Ahlskog JE, et al. Glutamic acid decarboxylase autoimmunity with brainstem, extrapyramidal, and spinal cord dysfunction. *Mayo Clin Proc* 2006; **81**: 1207–14.
- Saiz A, Blanco Y, Sabater L, et al. Spectrum of neurological syndromes associated with glutamic acid decarboxylase antibodies: diagnostic clues for this association. *Brain* 2008; **131**: 2553–63.
- Manto M, Laute M, Aguera M, Rogmond V, Pandolfo M, Honnorat J. Effects of anti-glutamic acid decarboxylase antibodies associated with neurological diseases. *Ann Neurol* 2007; **61**: 544–51.
- Stenström G, Gottsäter A, Bakhtadze E, Berger B, Sundkvist G. Latent autoimmune diabetes in adults. Definition, prevalence, β -cell function, and treatment. *Diabetes* 2005; **54**: S68–72.

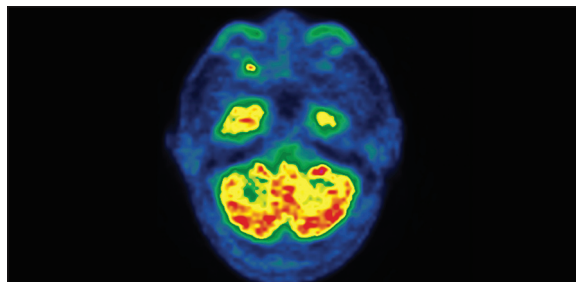


Figure: Autoimmune cerebellar ataxia
FDG-PET showing depressed glucose metabolism in the cerebellum.